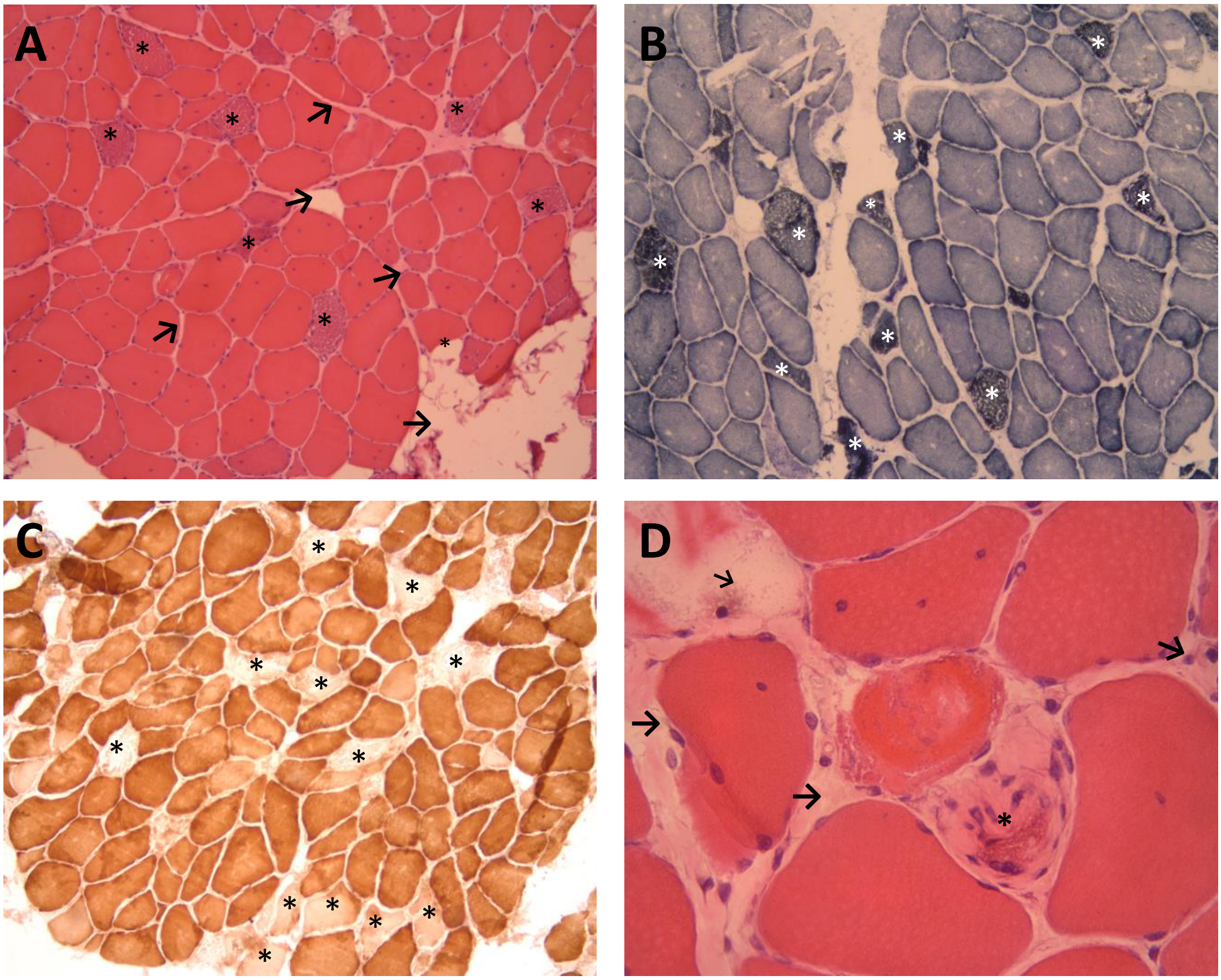

Figure S1. **Histological analysis of *post mortem* quadriceps.** Representative images of muscle sections showing numerous ragged-red fibers (A); hyper-reactive succinate dehydrogenase (SDH) fibers (B); cytochrome-c oxidase (COX) negative fibers (C); and necrotic fibers with myophagocytosis (D). *Altered fibers. Arrows, endomysial fibrosis and adipose tissue replacement. A-C 10x, and D 40x.